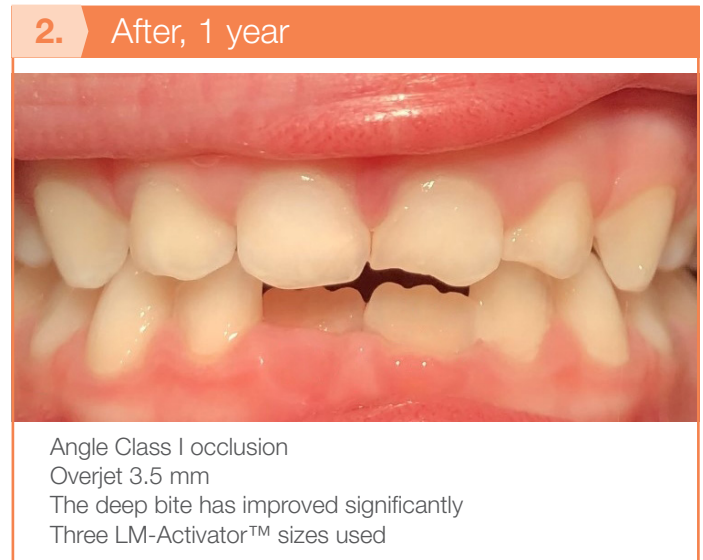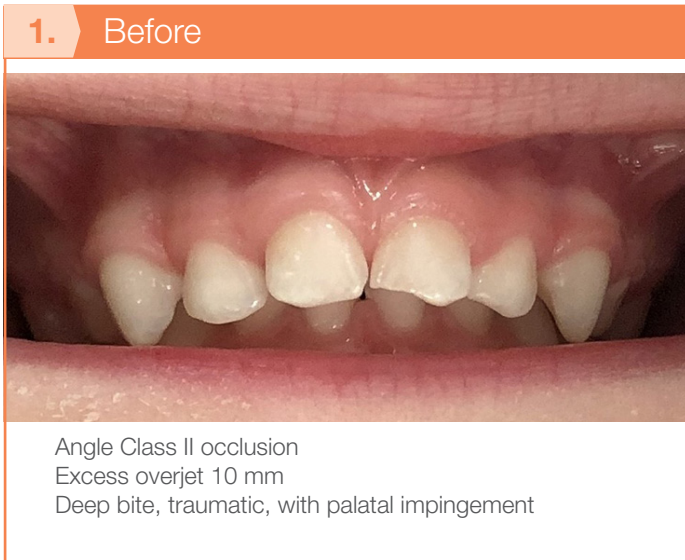


LM-Activator™ patient case

Boy 5 years old: Angle Class II - Deep bite, Overjet

- Excess overjet or increased horizontal overbite 10 mm, traumatic deep bite with palatal impingement, Angle Class II distal bite
- Mentolabial fold
- Labial defect, the lower lip tends to roll up behind the upper incisors
- Articulation disorders
- Eruption of permanent teeth is starting
- LM-Activator™ Low Short size 30 is taken into use (Dental assistant Annica Marjamaa and DDS Minna-Maria Tervonen)
- Follow-up appointments with the dental assistant at 4-month intervals



10/22 Minna-Maria Tervonen, DDS, Specialist in Orthodontics, Mehiläinen Länsi-Pohja, Kemi, Finland